

Nieuwe RCT's met als doel: meer patiënten succesvol behandelen

- Verbetering collaterale circulatie en bloeddruk verlaging
 - Nitroglycerine pleister in de ambulance
- Risico op bloedingen en andere complicaties reduceren
 - Geen intraveneuze rt-PA geven
- Verbeteren van microvasculaire reperfusie
 - Periprocedureel toedienen van: Acetylsalicylzuur en/of ongefractioneerde heparine
- Indicatie van IAT uitbreiden
 - IAT 6-24 uur na ontstaan van symptomen

CONTRAST

Collaboration for New Treatments of Acute Stroke

MR ASAP

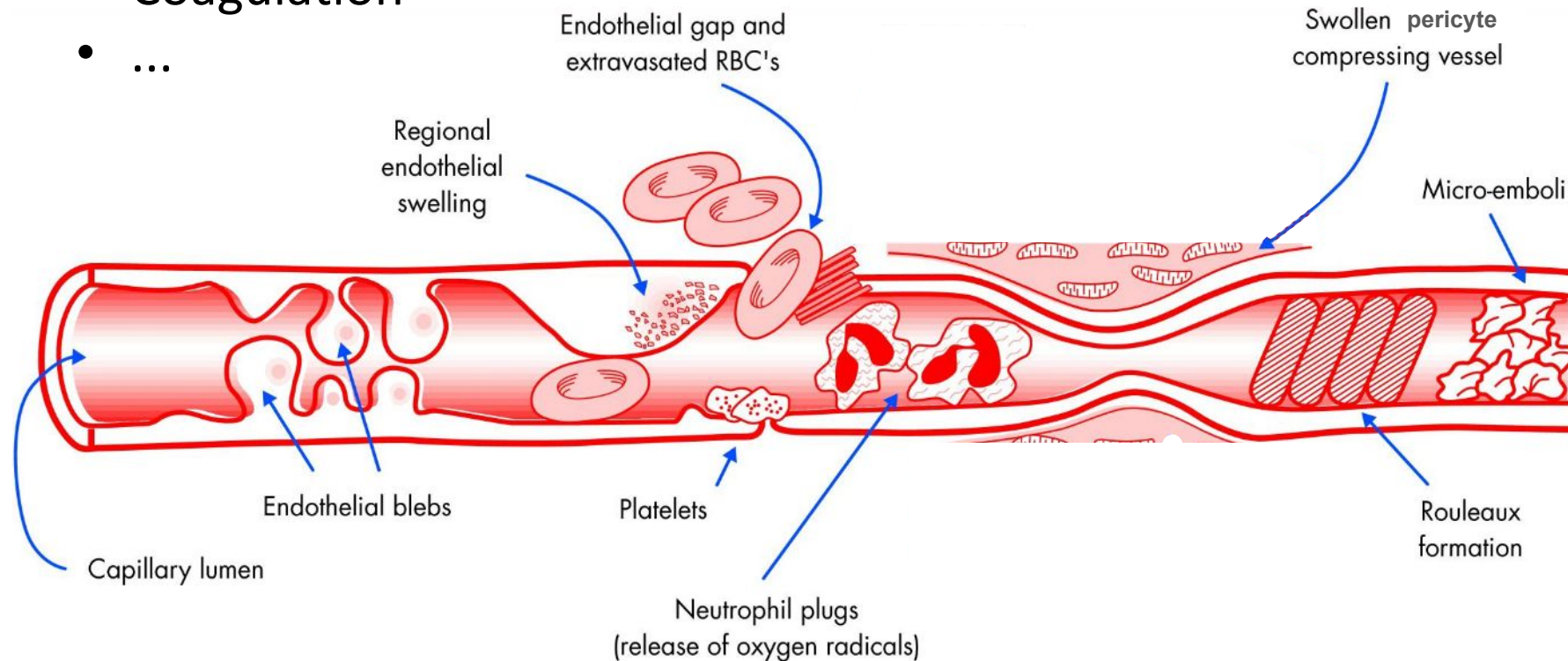
MR CLEAN **N** IV

MR CLEAN **MED**

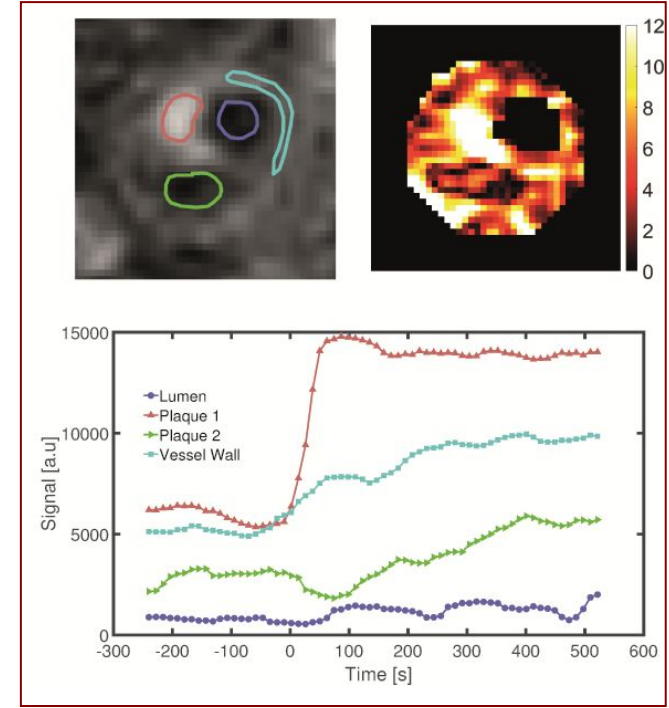
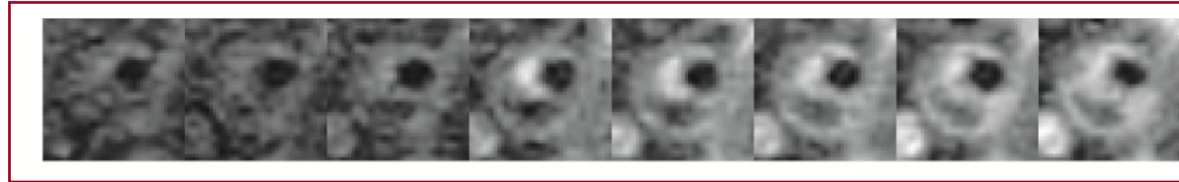
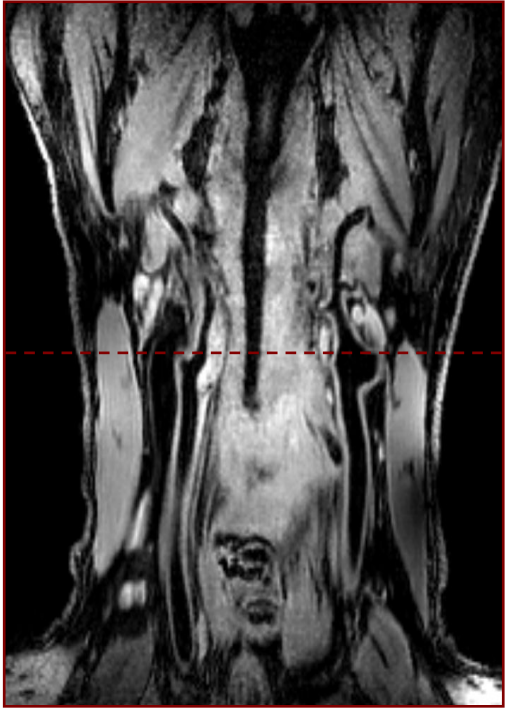
MR CLEAN LATE

Possible causes of incomplete microvascular reperfusion

- Endothelial impairment
- Leukocyte infiltration
- Microembolization
- Coagulation
- ...



Inflammation & validation 3D (DCE) MRI



Proteomics panel
FACS-WBC telling

PA na CEA

PET-CT 68-Gd-DOTATE